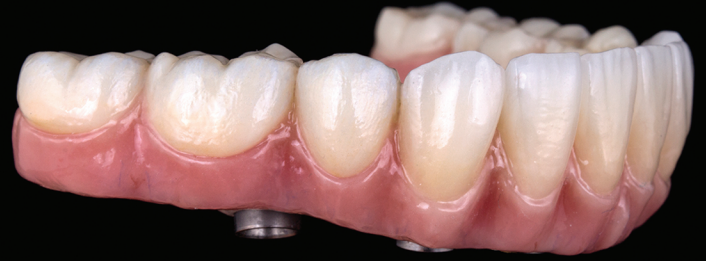

MANDIBULAR FULL ARCH ZIRCONIA HYBRID CASE STUDY



Celin Arce, DDS, MS, FACP

Assistant Professor, University of Alabama at Birmingham School of Dentistry, Restorative Sciences, Division of Prosthodontics, 1919 7th Avenue South
Birmingham, AL 35294 USA
celin@uab.edu



Matt Winstead, CDT

Vice-President of Oral Arts Dental Laboratories
2700 South Memorial Parkway
Huntsville, AL 35801
matt.winstead@oralartsdental.com

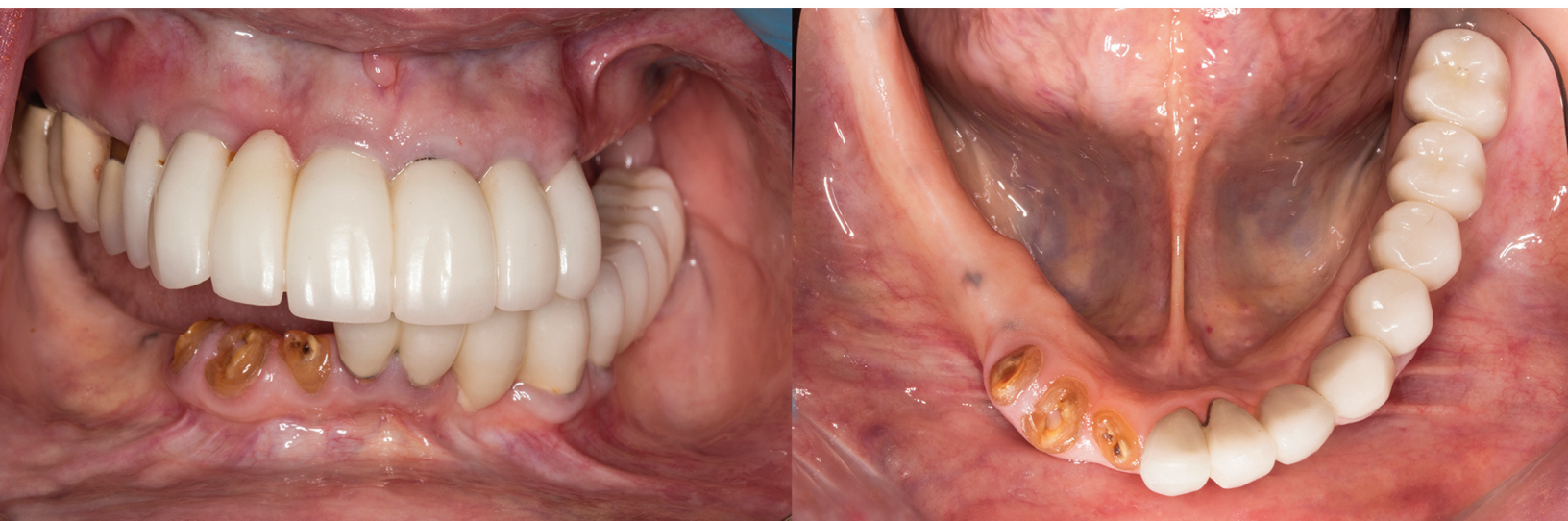INTRODUCTION

Full arch implant supported restorations have been documented to have high success rates. Many combinations of materials have been used for these type of restorations such as metal alloy-acrylic, metal alloy-composite, and metal alloy-ceramic. However, complications including fractured or debonded acrylic resin teeth, wear of opposing surfaces, ceramic chipping, difficulty in shade matching of acrylic and pink ceramic, lack of passive fit, and extensive work for repair after framework breakage have encouraged dentists to look for other material options. The following case study will present the clinical and laboratory protocol to fabricate a zirconia full arch prosthesis.

CASE STUDY

A 70 year old patient presented with fractured teeth and multiple failing restorations. It was determined the mandibular teeth were not restorable and treatment plan was for a mandibular fixed detachable prosthesis with 5 implants. Due to finances of the patient, the maxillary arch will be restored after the mandibular arch is finished.

Figure 1. Pre-operative condition of the patient from frontal and occlusal view



A full thickness flap was performed and extraction of remaining mandibular teeth with alveoloplasty was done to create restorative space and achieve an even ridge. A clear duplicate surgical guide was used for implant position and distribution. And five BioHorizons Tapered Internal implants were placed using a second stage approach.

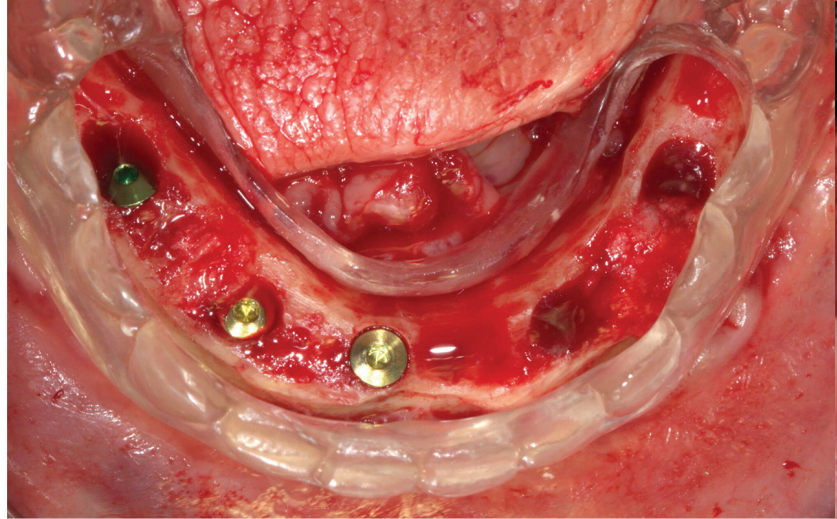


Figure 2. Implant placement surgery (Surgery by Dr. Kalee Claussen)

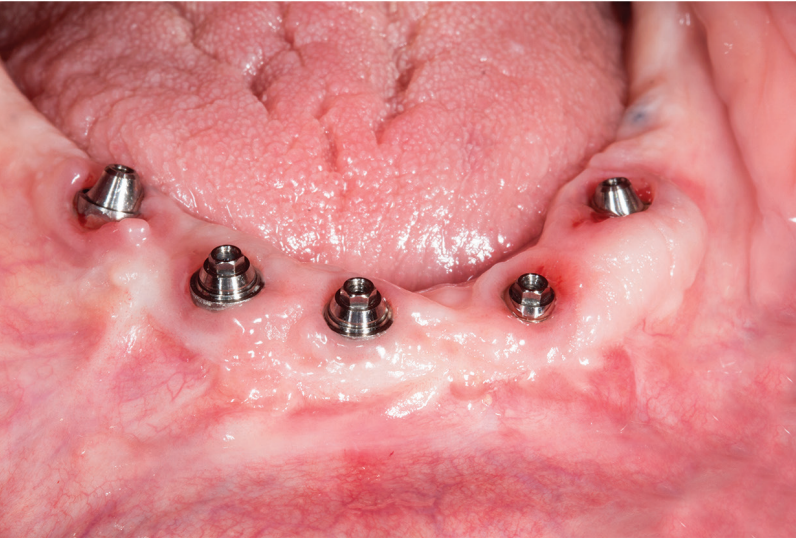

Figure 3. Multi-Unit abutments in place

After an uneventful healing period, uncover of the implants was done and Multi-Unit Abutments were placed and torqued to 30NCM.

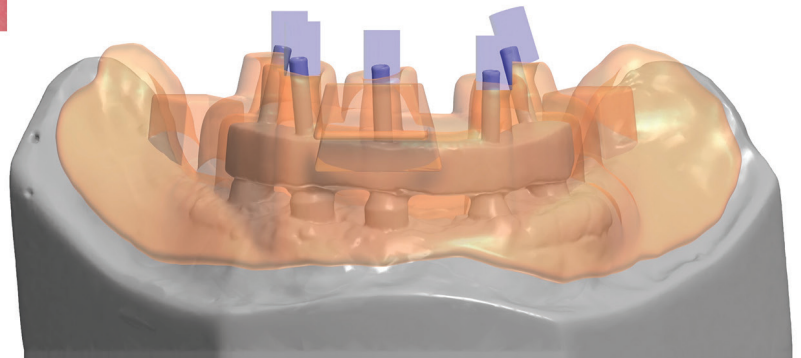


Figure 4.

A CAD-CAM generated custom tray was designed using 3Shape software with precise open tray holes and custom tray was 3D printed in resin.

Figure 4 and 5. 3D Printed Custom Tray

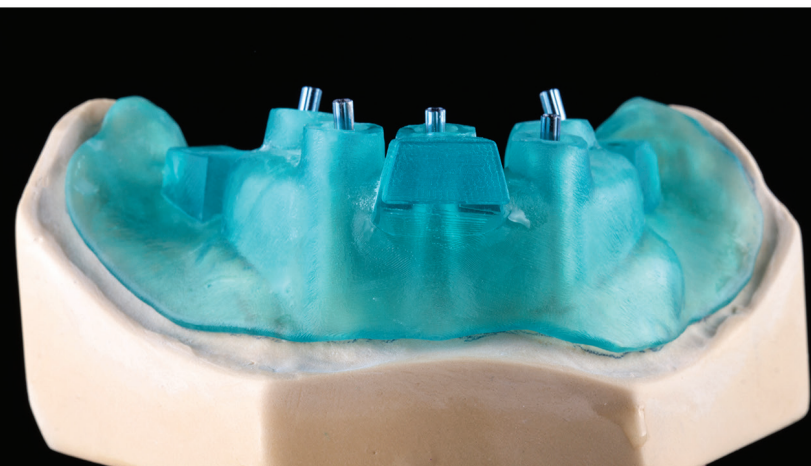

Figure 5.

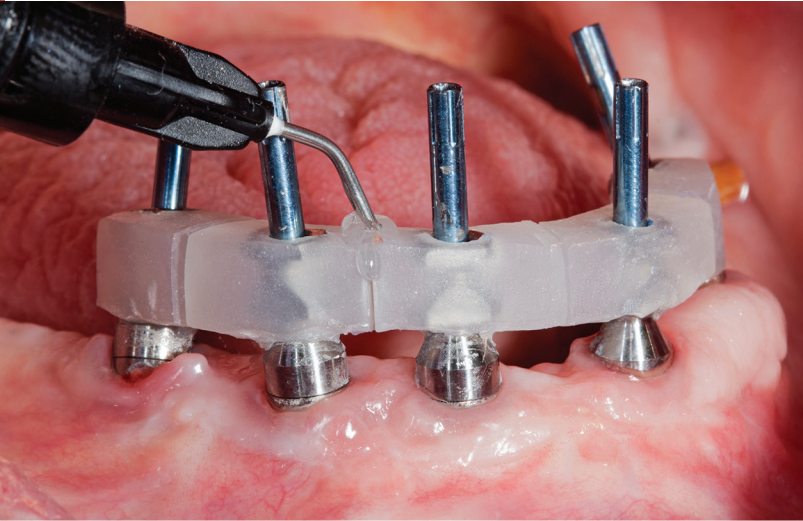


Figure 6. Open tray impression posts with sectioned jig

Open tray impression posts were placed with sectioned jig and joined intraorally with flowable light cure composite (PrimoPattern Clear, Primotec USA).

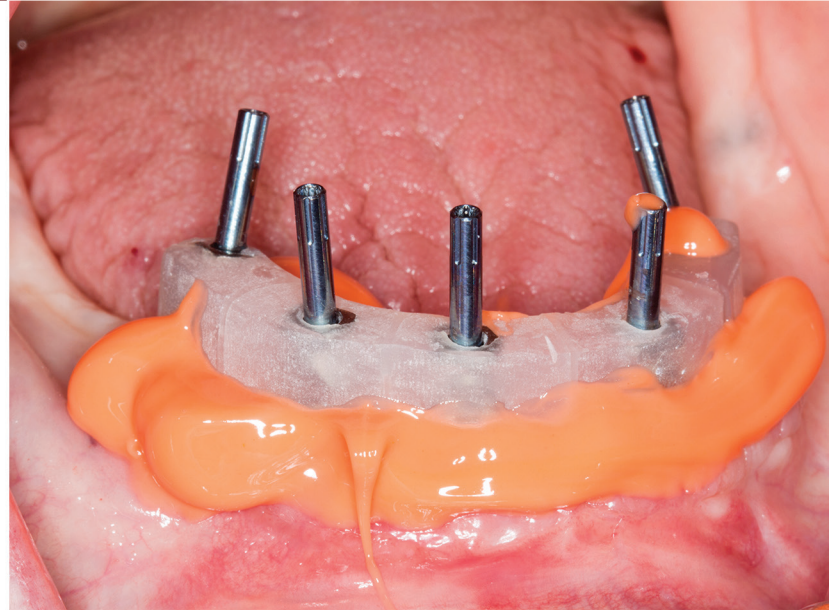
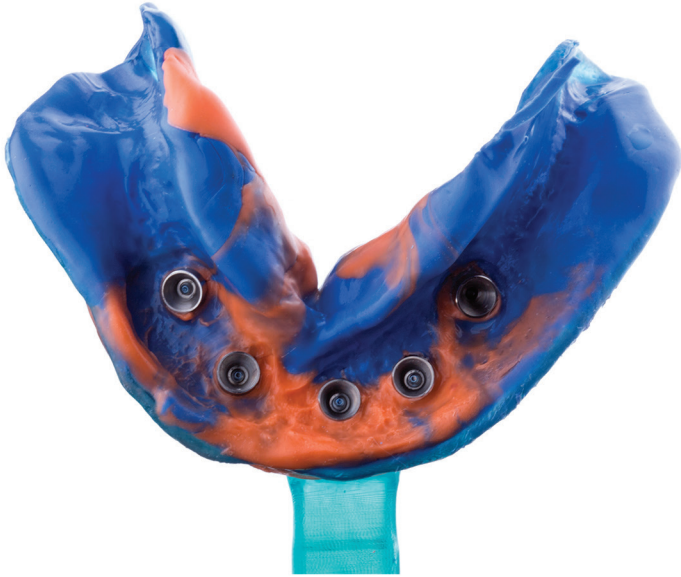

Figure 7. Final impression was done with extra light PVS around impression posts and monophasic viscosity for the impression tray (Virtual XD, Ultradent Inc)

After master cast fabrication, maxilomandibular records were taken and a wax teeth set-up was done to determine teeth position and vertical dimension.

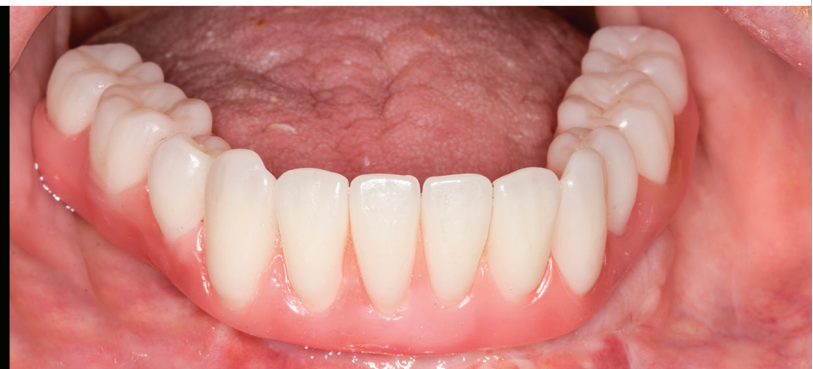
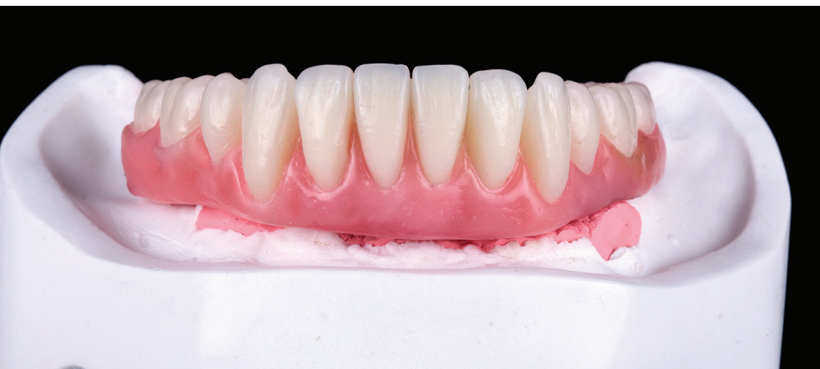
Figure 8. Wax teeth set-up

Wax set-up was scanned and digitized to fabricate a poly-methylmethacrylate (PMMA) restoration. The design software for the aforementioned scanner had the ability to uniformly cut back the gingival area of the prosthesis to a desired thickness so space would be provided to apply tissue-colored composite resin to esthetically simulate soft tissue. After milling the PMMA blank, tissue-colored composite (Gradia, GC International) was applied and subsequently finished and polished. The esthetics, lip support, occlusion were then confirmed intraorally.

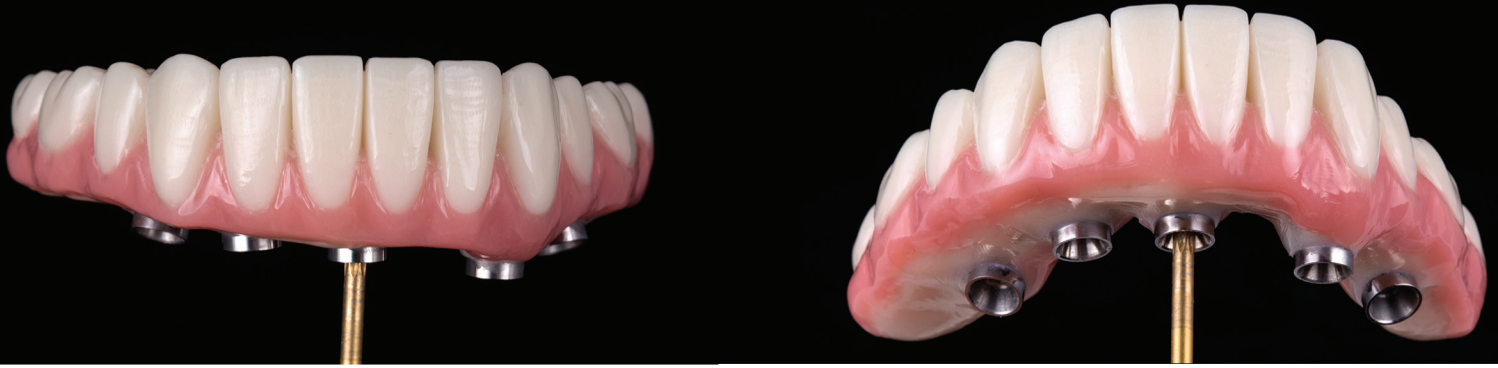

Figure 9. PMMA restoration frontal view

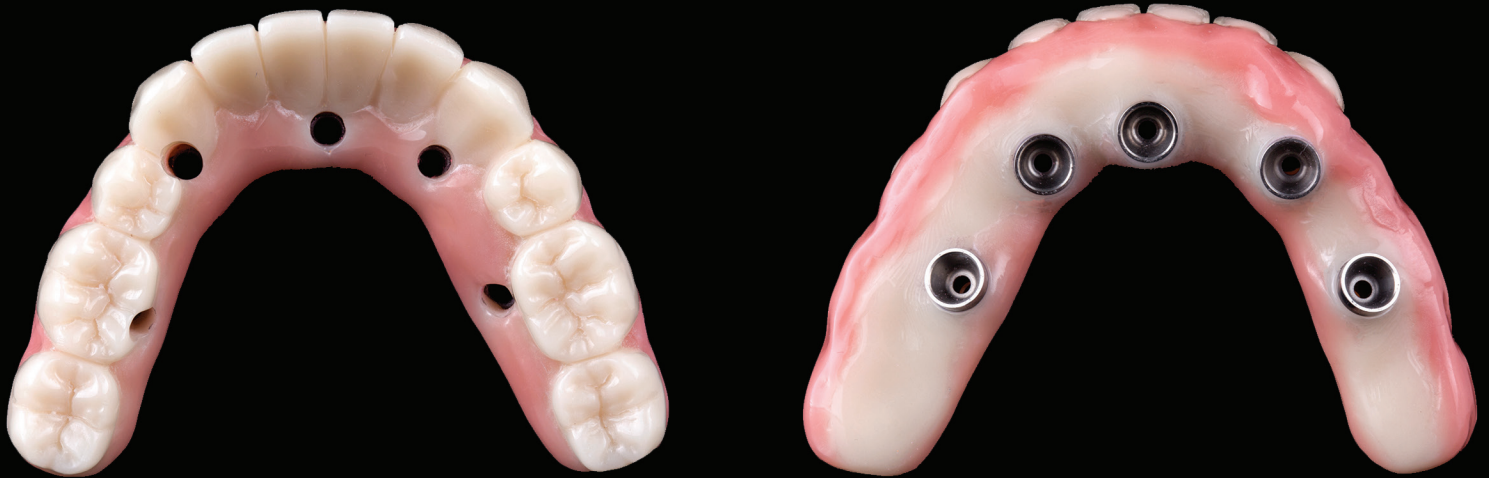

Figure 10. PMMA restoration intaglio and cameo view

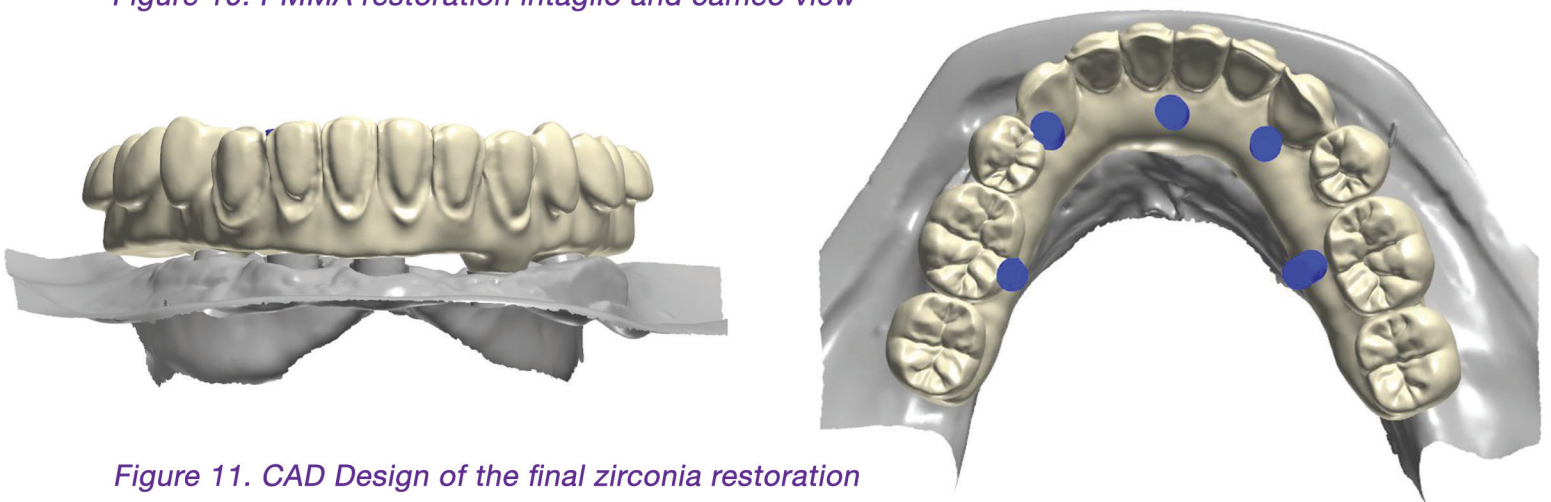


Figure 11. CAD Design of the final zirconia restoration

The final design of the zirconia prosthesis was done with monolithic zirconia for posterior teeth and only facial cut-back from canine to canine for porcelain veneering (Noritake CZR) and pink porcelain for the soft tissue area (GC Initial). A zirconia blank (Argen Z Esthetic 22 × 95 mm, Argen) was used for milling the definitive prosthesis.



Figure 12. Full arch prosthesis after being milled prior to sintering

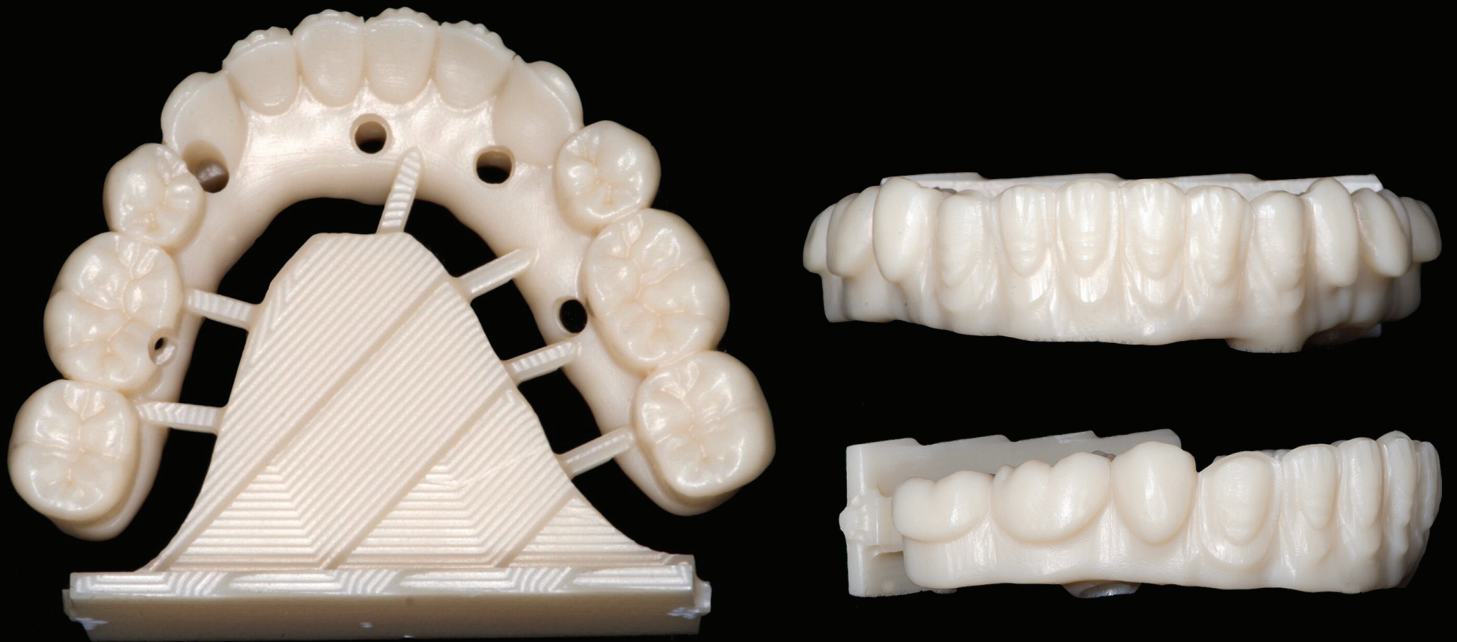

Figure 13. Zirconia restoration after being sintered

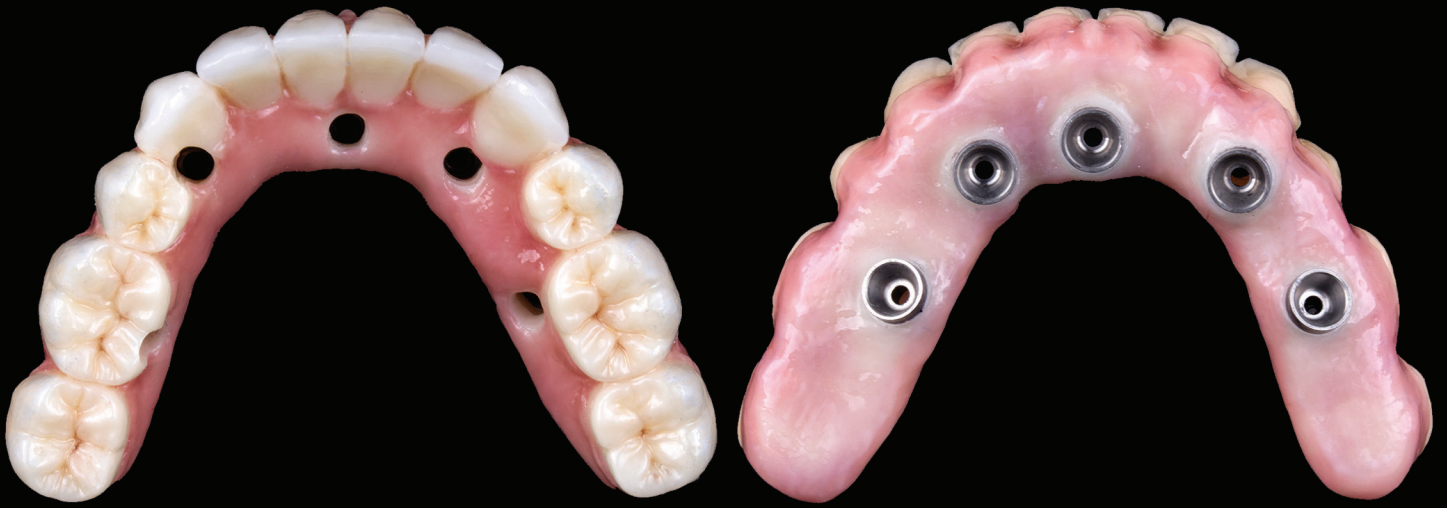

Figure 14. Final zirconia restoration from intaglio and cameo view

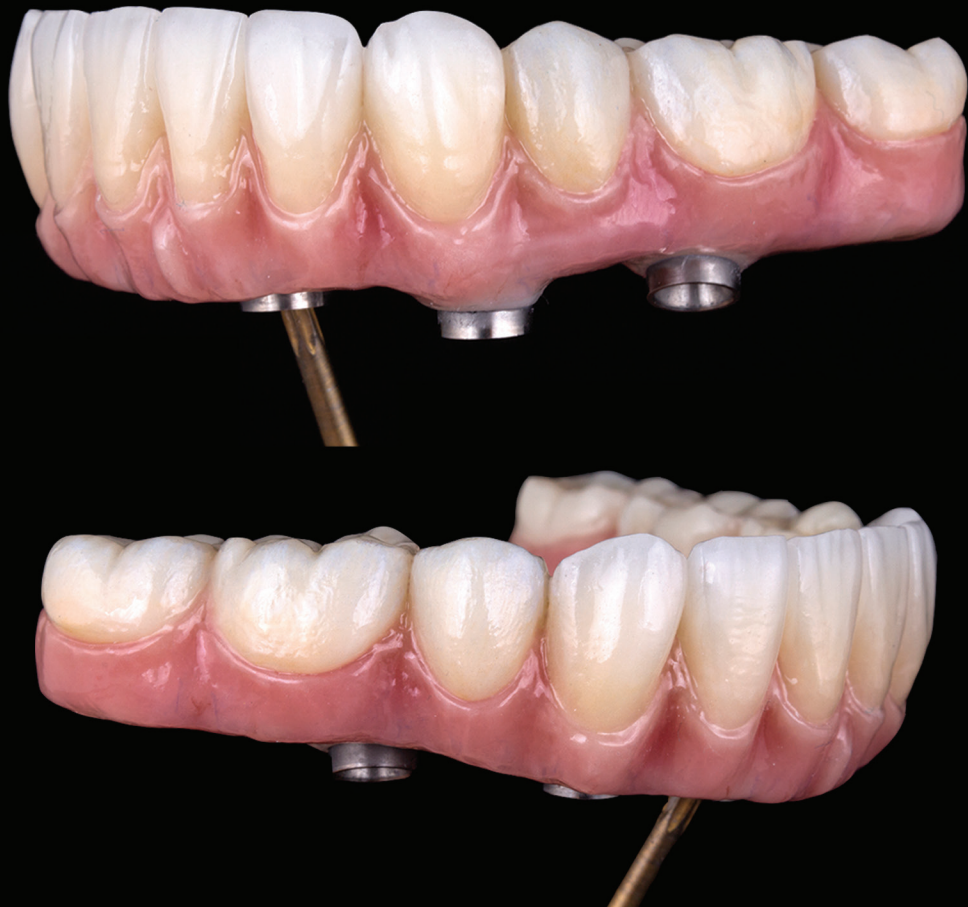

Figure 15. Final zirconia restoration from lateral view

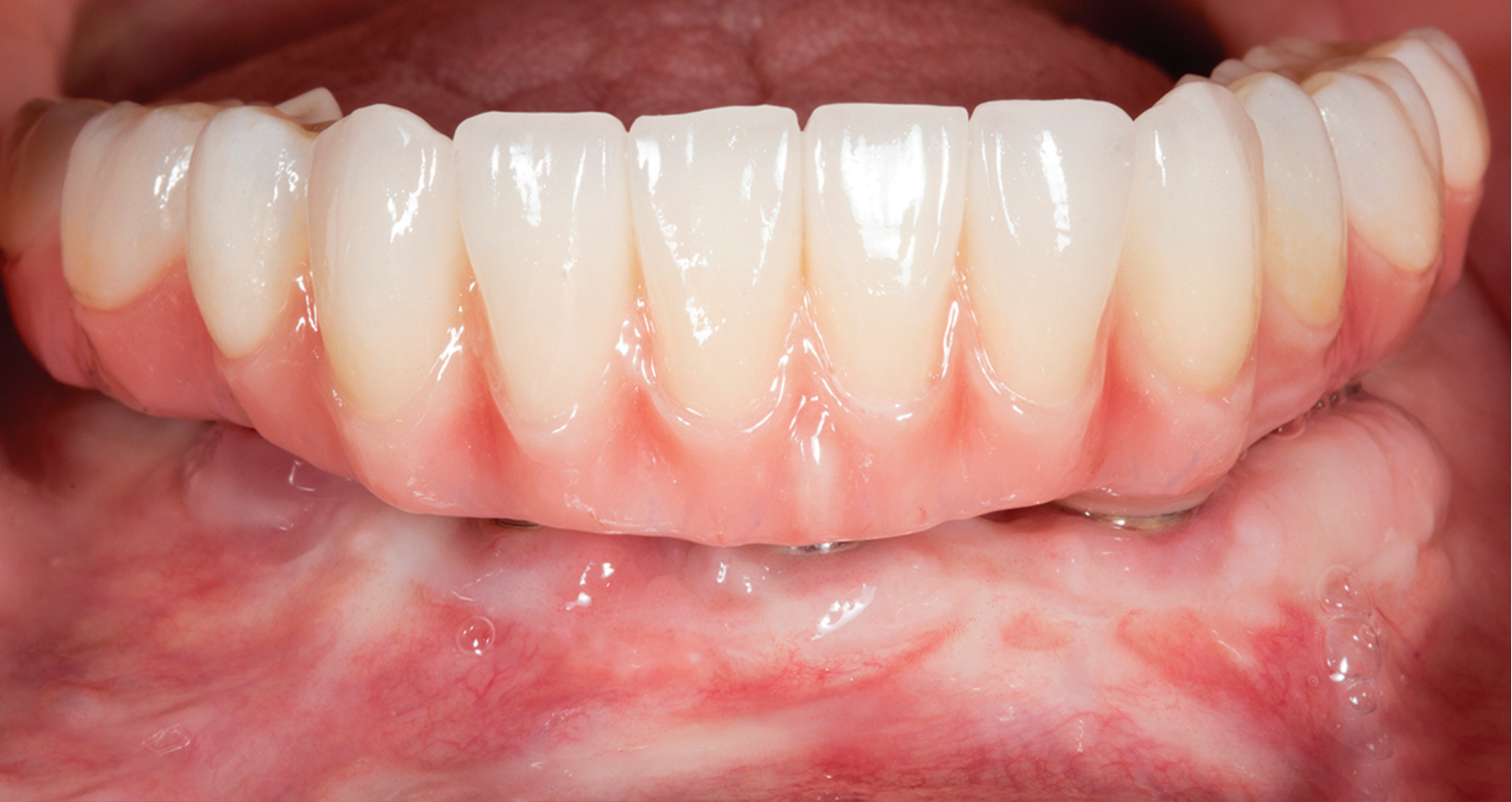

Figure 16.

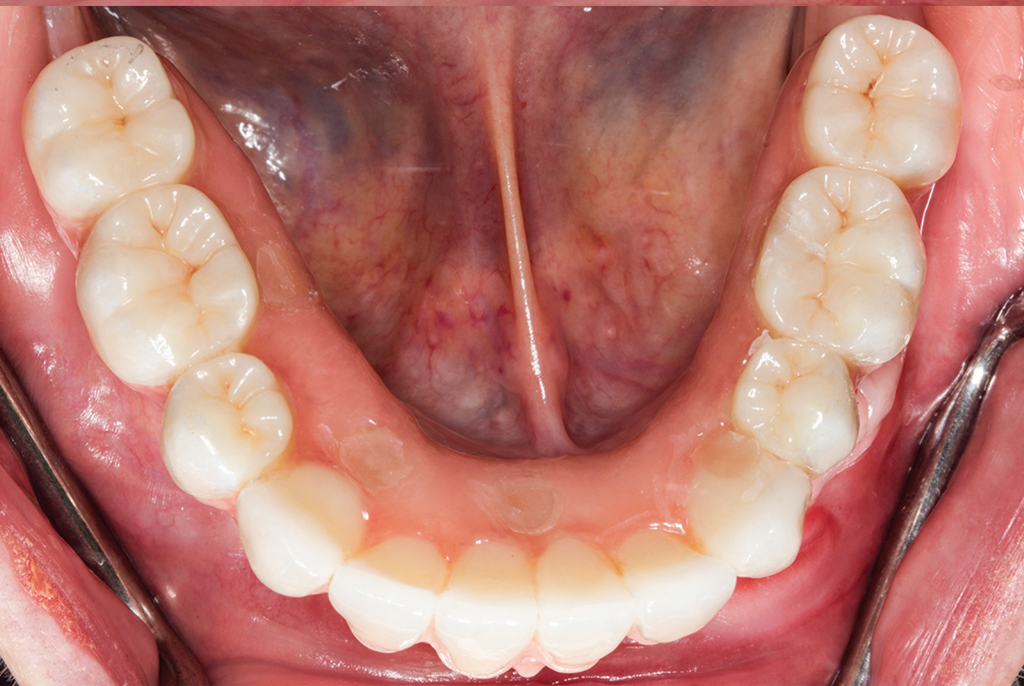

Figure 16 and 17. Final restoration placed intraorally, screw-access sealed with composite

Figure 17.

CONCLUSION

The use of a zirconia CAD/CAM-milled restoration is a great treatment material option for full arch implant supported fixed prosthesis. Some of the benefits are accuracy, reduced veneering porcelain, and minimal occlusal adjustments. A full occlusal monolithic framework and minimal facial cutback can diminish chipping of the veneered porcelain.

However, the fabrication is technique sensitive and should follow the appropriate clinical and laboratory steps discussed in this case study. The outcome of the present patient report showed high success in function, aesthetics, phonetics, and high patient satisfaction.



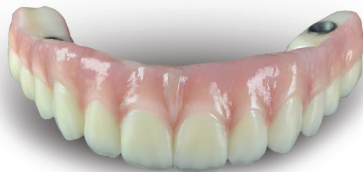Celin Arce, DDS, MS, FACP

Doctor in Dental Surgery, Universidad Latina de Costa Rica (2005-2009)
Advanced Education in Prosthodontics, University of Alabama at Birmingham, USA (2012-2015)
Master of Science in Clinical Dentistry, University of Alabama at Birmingham, USA (2013-2016)
Board Certified by the American Board of Prosthodontics
Diplomate of the American Board of Prosthodontics.
Fellow of the American College of Prosthodontists.
Assistant Professor at the Restorative Sciences Department at University of Alabama at Birmingham, USA (2015 to present)

Active member of numerous organizations: American Prosthodontic Society, Academy of Osseointegration and American Academy of Cosmetic Dentistry
Lecturer for national conferences and continuing education courses
Practice limited to dental implants and high end complex oral rehabilitations

\$250
OFF*

Element-Z™ Screw Retained Hybrid



From
OralArts
DENTAL LABORATORIES HUNTSVILLE, ALABAMA

800-354-2075
www.oralartsdental.com

*Send this coupon in with your final processing step and discount will be applied to final prosthesis invoice. May not be combined with any other offer or discount. One coupon per dr/practice. Account must be current with no outstanding balances for coupon to be applied. Coupon Code:CLINICAL250